

3

"You Know, Doc, I Have This Thing"

You know, doc, I have this thing . . ."

No matter where I go—a party, a social function, a business meeting—I am invariably offered the opportunity, once my profession becomes known, to examine and comment on a range of skin “things” that friends, colleagues, and acquaintances have become concerned about. Typically, interest in particular skin lesions follows on the heels of a news story about a famous individual who has been diagnosed with melanoma or the knowledge that a family member has had “something” removed. Alternatively, concern about skin things relates more than ever to a preoccupation with the signs of aging. In a social setting, it has been my personal policy not to be offended by individuals seeking reassurance that their “things” are not serious. At least twice, people I met outside of my office showed me lesions that proved to require prompt attention. That they felt comfortable enough to raise the question may have been lifesaving. Nonetheless, it is true that the vast majority of lumps, bumps, and spots that we all have (and continue to accrue as time passes) are not malignant and bear no risk of cancer. However, they serve an important medical purpose: they often bring people in to see the dermatologist, who then has an opportunity, through a full-body skin exam, to identify whether more serious conditions exist.

In this chapter, I will describe the most common spots, the lesions that individuals bare in the host's kitchen, the restaurant's bathroom, or even in a corner of the hotel's meeting hall. Full-color examples of many of these are provided in the "Color Atlas of Your Skin" (see insert).

The best way to think about any spots you may have is to identify the color. Does the color disappear when you put pressure on it? Is it a single spot, or are there many others just like it in the same area or elsewhere? Do the spots occur only where the skin is exposed to the sun? How long has the lesion been there? Did it occur within the past 24 hours or has it been present for the past several weeks or months?

▪ BROWN SPOTS

Spots that are brown have pigment in them. The brown coloration is caused by the pigment-producing melanocyte cell, or it can be the result of pigmentation from previous injury or even a side effect of certain medications. Blue spots may also result from the presence of pigmentation in the skin, but the pigmentation is deposited deeper, in the dermis, so as light reflects off it in a process called the Tyndall effect the growth appears blue rather than brown.

Brown spots on sun-exposed areas can be one of several things: so-called liver spots, which are due to chronic sun exposure; freckles; melasma, which appears as patches of pigmentation as seen in the mask of pregnancy; or lentigo maligna, a condition that requires serious attention because of the risk that it could turn into invasive melanoma.

Solar lentigo, also called liver spot or sun spot, generally occurs on the face and the backs of the hands. It can occur in men and women and begin in middle age, occurring mostly in fair-skinned individuals of northern European descent.

Freckles are often present throughout life and are manifested by numerous small brown non-scaly spots that become darker with sun exposure. They begin in childhood and are most common in fair-skinned children with blond or red hair and blue or green eyes. The tendency to get freckles is probably inherited.

Of all the brown spots that can develop on the face with age, the one that is most alarming is *lentigo maligna*. This type of flat, dark patch is often present for many years; it may have variation in pigmentation including brown, blue, black, and sometimes red. The edges of the patch are frequently irregular and maplike.

Lentigo maligna occurs in sun-exposed areas, most often on the face and neck. Although it is usually seen in older, fair-skinned individuals, recently it has become clear that there has been an increase in this condition in younger individuals, even in their forties. Over many years lentigo maligna can transform into invasive melanoma, and for this reason it should be approached aggressively.

Melasma is a blotchy tan discoloration that affects the cheeks, primarily under the eyes and cheekbones. It can affect the chin and upper lip as well, but is usually not seen on the backs of the hands or the chest. Melasma is very common in women who have been pregnant. In fact, it usually appears first during pregnancy, when it is known as *chloasma* or the *mask of pregnancy*. Melasma can be exacerbated by taking oral contraceptives. All this tells us that the pigmentation in some way is related to estrogen, but we are not certain about what that mechanism is since melasma is occasionally seen in men too. The treatment options for this condition are relatively limited, which makes melasma a frustrating condition to dermatologists. We have tried using laser, chemical peel, and bleaching creams, and the best thing that can be said is that treatment must be customized to the individual. This condition is not in any way dangerous.

Another common pigmented patch is the café-au-lait spot. These smooth, benign, uniformly pigmented, tan patches are usually larger than half an inch. Although they occur most frequently on the trunk, they can be seen anywhere on the body. About 10 percent of all people have one to three spots like this. Rarely, café-au-lait spots are a sign of an inherited condition. Albright's syndrome, which includes premature puberty and bone abnormalities, can have a café-au-lait spot as a skin sign. Neurofibromatosis, a condition incorrectly thought to be "elephant man disease" may also be associated with multiple café-au-lait spots. In this condition, spots are only a small part of a syndrome that includes multiple fleshy nodules or fibromas over the whole body.

Sometimes pigmentation changes arise after an inflammatory event has taken place. Inflammation is simply the process by which the body tries to fix a problem. For example, if you scratch yourself, your body immediately senses that something has gone wrong and sends cells into the area that release chemicals, which set about fixing the problem and restoring the skin to its normal state. In doing so, there is redness, the result of the ingrowth of new blood vessels and release of compounds that assist in warding off any infection, which might now take advantage of the break in the skin. Under normal circumstances the body goes about its business and cor-

rects the problem. What is often left is something called postinflammatory hyperpigmentation, in which the pigment melanin has been deposited in the dermis. This will take time to resolve, but is otherwise not a problem.

When pigmented spots occur in areas that are not sun-exposed, we usually think of less serious conditions, such as a fungal infection, benign moles, or congenital nevi (the moles with which we are born). Any new or changing brown spot on the palms or soles should be investigated immediately because of the possibility of melanoma. Your dermatologist will be able to determine if there is any reason for concern.

Another common complaint is a black nail. People often think that this represents a melanoma, and indeed it can. More often, however, it is so-called *talon noir*, which is the result of a stubbed toe or other trauma. The bruise or hemorrhage under the nail can look just like melanoma.

Pigmentation can color the skin more broadly than just in particular spots. When *hyperpigmentation* occurs over the whole body, it can be an indication of an internal problem. For instance, Addison's disease, the condition that afflicted President John F. Kennedy, can cause generalized darkening of the skin. This is due to failure of the adrenal glands, which sit on the top of the kidneys, to function properly. Another internal condition with brown skin discoloration is arsenic poisoning. The accidental ingestion of arsenic was far more common when the chemical was used as an insecticide on farms and elsewhere. While internal cancer could develop as a result of this poisoning, it was the outward manifestation—rough pits on the palms and the development of skin cancers—that often signaled that something was wrong.

A few more conditions merit a brief mention. Cushing's syndrome, in which the adrenal gland produces excessive amounts of cortisol, can manifest itself with facial hair, new outbreak of acne, black-and-blue marks, and stretch marks. A rare blood condition called hemochromatosis can result in bronzing of the skin, hair loss, and spoonlike changes in the nails.

▪ LIGHT SPOTS AND WHITE SPOTS

On the other end of the color spectrum are spots that lack pigmentation completely or are lighter than the surrounding skin. So-called depigmented areas can be indicative of a condition called vitiligo, which has been made most famous by Michael Jackson. Hypopigmented macules are spots that have decreased pigmentation and could represent a superficial fungus infection called tinea versicolor or some other disease.

Conditions that represent the absence of pigmentation include albinism. In this inherited condition there is a total body loss of pigmentation. People with albinism are especially at risk for developing skin cancer because they lack the natural pigmentation that protects their DNA from the damaging effects of the sun.

▪ RED SPOTS AND PATCHES

Red spots generally reflect the presence of new or active blood vessels. In children, small spider angiomas may develop, which eventually clear up on their own. These are about 1 millimeter in size with a central "body" from which vessels extend just like the legs of a spider. With the advent of safe lasers many parents often opt to have these patches treated. Lesions like this can also develop during pregnancy and are believed to be related to increased blood levels of estrogen.

Probably the best known example of a red patch is hives. Hives are red, often raised patches that sometimes have a surrounding white halo. They can be as small as the point of a pencil or as wide as an egg. Hives, which can occur anywhere on the body including the lips and tongue, are frequently itchy. Medications, especially aspirin and penicillin, and preservatives in foods, fish, nuts, and berries can cause hives. Other culprits include viral infections, intestinal infections, bug bites, and even environmental factors such as sunlight, cold, and pressure. Hives normally go away on their own without any special treatment, but occasionally an oral antihistamine is helpful.

Raynaud's phenomenon is a condition in which the fingertips and toes are very sensitive to cold. As a result these areas turn white, then become purple and red within several minutes. Other terminal ends of the body, such as the ears and nose, can also be affected. Although more common in females, it can occur in males. If an actual ulcer develops on the fingers, Raynaud's may signal an underlying medical problem.

Flushing syndromes are quite common, and the most notable of them is rosacea. In this condition, the central facial redness is hard to control. Many individuals, especially those of northern European descent, develop telangiectasias, often referred to as broken blood vessels. These can be due to heredity, rosacea, or chronic sun exposure. Telangiectasias develop quite often on the face as small broken capillaries. The term comes from Greek words meaning "dilated ends of the blood vessel."

A rare condition called HHT (standing for Hereditary Hemorrhagic

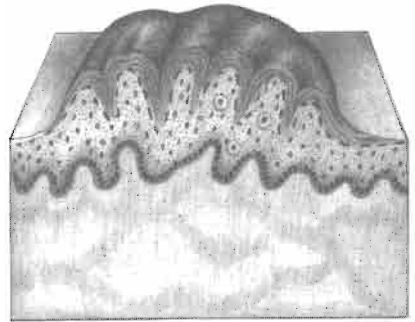
Telangiectasia) is being investigated at Yale and elsewhere. People with this condition have multiple telangiectasias on the lips, face, fingers, and the rest of the skin. The special problem is that the same lesions may exist inside the body, in the brain, lung, and elsewhere, where they can cause serious problems—they can lead to hemorrhage and stroke. Individuals with multiple telangiectasias that fit this pattern should be evaluated for Rendu-Osler-Weber syndrome, which is the traditional name of HHT.

▪ FLESH-COLORED BUMPS

The most common flesh-colored growths are skin tags, which appear with age around the neck and in the armpits.

On the face, a common dome-shaped, flesh-colored bump is the fibrous papule. It's important for your doctor to recognize these, because they can be confused with basal cell cancer.

Seborrheic keratoses and warts are two common, benign growths that are often flesh-colored.



[Seborrheic Keratosis]

Note: For more on each of these dermatologic growths or to locate additional information see the index.